



Teaching bone marrow procedures at pelvic and sternal sites: a high fidelity anatomy simulation

L'enseignement des techniques de prélèvement de moelle osseuse au niveau du bassin et du sternum : une simulation anatomique haute fidélité

Heather VanderMeulen, Marissa Laureano, George Hu, Wendy Lim, Catherine Ross, Bruce Wainman et Michelle P Zeller

Volume 12, numéro 2, 2021

URI : <https://id.erudit.org/iderudit/1077202ar>
DOI : <https://doi.org/10.36834/cmej.69475>

[Aller au sommaire du numéro](#)

Éditeur(s)

Canadian Medical Education Journal

ISSN

1923-1202 (numérique)

[Découvrir la revue](#)

Citer ce document

VanderMeulen, H., Laureano, M., Hu, G., Lim, W., Ross, C., Wainman, B. & Zeller, M. (2021). Teaching bone marrow procedures at pelvic and sternal sites: a high fidelity anatomy simulation. *Canadian Medical Education Journal / Revue canadienne de l'éducation médicale*, 12(2), e106–e109.
<https://doi.org/10.36834/cmej.69475>

Résumé de l'article

Énoncé des implications de la recherche : La ponction et la biopsie de la moelle osseuse sont d'une importance capitale pour le diagnostic de nombreuses pathologies hématologiques. Nous décrivons un atelier pratique, axé sur l'anatomie, qui permet aux apprenants de faire des prélèvements de moelle osseuse sur des cadavres. Les participants ont notamment appris à effectuer des ponctions sternales, une intervention qui est plutôt rare dans la pratique réelle. Ils indiquent avoir apprécié l'atelier, grâce auquel ils ont pris confiance pour pratiquer la technique. L'atelier est une occasion précieuse pour les apprenants d'acquérir une habileté technique dans un environnement sûr et haute fidélité. Étant donné son caractère pratique, les programmes de résidence pourraient aussi l'adapter dans un contexte d'observation directe et d'évaluation.

© Heather VanderMeulen, Marissa Laureano, George Hu, Wendy Lim, Catherine Ross, Bruce Wainman et Michelle P Zeller, 2021



Ce document est protégé par la loi sur le droit d'auteur. L'utilisation des services d'Érudit (y compris la reproduction) est assujettie à sa politique d'utilisation que vous pouvez consulter en ligne.

<https://apropos.erudit.org/fr/usagers/politique-dutilisation/>

érudit

Cet article est diffusé et préservé par Érudit.

Érudit est un consortium interuniversitaire sans but lucratif composé de l'Université de Montréal, l'Université Laval et l'Université du Québec à Montréal. Il a pour mission la promotion et la valorisation de la recherche.

<https://www.erudit.org/fr/>

Teaching bone marrow procedures at pelvic and sternal sites: a high fidelity anatomy simulation

L'enseignement des techniques de prélèvement de moelle osseuse au niveau du bassin et du sternum : une simulation anatomique haute fidélité

Heather VanderMeulen,¹ Marissa Laureano,² George Hu,³ Wendy Lim,⁴ Catherine Ross,⁵ Bruce Wainman,⁶ Michelle P Zeller⁷

¹Department of Medicine, University of Toronto, Ontario, Canada; ²Department of Medicine, McMaster University, Ontario, Canada; ³Department of Health Sciences, McMaster University, Ontario, Canada; ⁴Division of Hematology and Thromboembolism, McMaster University, Ontario, Canada; ⁵Division of Pathology and Molecular Medicine, McMaster University, Ontario, Canada; ⁶Department of Pathology and Molecular Medicine; Division Director of Anatomy and Director of the Education Program in Anatomy, McMaster University, Ontario, Canada; ⁷McMaster Centre for Transfusion Research, Department of Medicine McMaster University and Canadian Blood Services, Ontario, Canada

Correspondence to: Dr. Heather VanderMeulen, Department of Hematology C. David Naylor Building 6th Floor 6 Queen's Park Crescent West, Toronto ON Canada M5S3H2; email: heather.vandermeulen@medportal.ca

Published ahead of issue: January 28, 2021; published April 30, 2021. CMEJ 2021, 12(2) Available at <http://www.cmej.ca>

© 2021 VanderMeulen, Laureano, Hu, Lim, Ross, Wainman, Zeller; licensee Synergies Partners

<https://doi.org/10.36834/cmej.69475>. This is an Open Journal Systems article distributed under the terms of the Creative Commons Attribution License.

<https://creativecommons.org/licenses/by-nc-nd/4.0> which permits unrestricted use, distribution, and reproduction in any medium, provided the original work is cited.

Implication Statement

The bone marrow aspirate and biopsy procedure are fundamental to the diagnosis of many hematologic pathologies. We describe a hands-on, anatomy-based workshop that allows learners to practice bone marrow procedures on cadavers. Notably, participants learned how to perform sternal aspirates: a procedure rarely performed in real-life practice. Learners valued the experience and described increased comfort with the procedure after the workshop. This workshop provides a valuable opportunity for trainees to learn a procedural skill in a safe, high fidelity environment. Given its hands-on nature, residency training programs could also adapt it for direct observation and trainee assessment.

Énoncé des implications de la recherche

La ponction et la biopsie de la moelle osseuse sont d'une importance capitale pour le diagnostic de nombreuses pathologies hématologiques. Nous décrivons un atelier pratique, axé sur l'anatomie, qui permet aux apprenants de faire des prélèvements de moelle osseuse sur des cadavres. Les participants ont notamment appris à effectuer des ponctions sternales, une intervention qui est plutôt rare dans la pratique réelle. Ils indiquent avoir apprécié l'atelier, grâce auquel ils ont pris confiance pour pratiquer la technique. L'atelier est une occasion précieuse pour les apprenants d'acquérir une habileté technique dans un environnement sûr et haute fidélité. Étant donné son caractère pratique, les programmes de résidence pourraient aussi l'adapter dans un contexte d'observation directe et d'évaluation.

Introduction

The bone marrow biopsy and aspirate is an essential procedure for diagnosing many hematologic diseases, and an understanding of the relevant anatomy is crucial for patient safety.

However, anatomy is rarely taught in postgraduate medical education.¹ Simulation aims to recreate real-life patient scenarios and allows trainees to learn in a hands-on manner.² With this in mind, cadaveric simulation can be a valuable method for teaching procedural skills.^{3,4}

Innovation

We created a high-fidelity simulation with cadavers to teach bone marrow aspiration and biopsy (eSupplement). Part 1a includes a video outlining landmarking and technique, and Part 1b is an anatomist-led review of prepared specimens. Part 2 provides participants the opportunity to observe and practice bone marrow procedures under the guidance of a hematologist.

We offered the workshop on three occasions from 2016 to 2019. Fourteen hematology trainees, two faculty members, one physician assistant, and two internal medicine residents participated. Only one of the participants had previously performed a sternal aspirate. The estimated cost of this workshop for 12 participants is approximately \$5000 CAD.¹

Evaluation

With their consent, nine participants completed pre- and post-workshop surveys (Appendix A) to assess their perceptions and comfort with the procedures. We compared bone marrow biopsies performed by trainees to specimens collected by hematology staff that did not participate in the workshop. This study was exempt from Research Ethics Board (REB) review by the Hamilton Integrated REB.

Post-workshop, participants reported improved comfort with bone marrow procedures (mean 3.8) and knowledge of the relevant anatomy (mean 4.4), (1 = no change; 3 = some improvement; 5 = significant improvement). Participants anticipated the workshop would impact their future bone marrow biopsy technique (mean 3.9), (1 = no change, 3 = some adjustments, 5 = significant change). The diagnostic yield and biopsy results for trainees and staff hematologists are outlined in Table 1.

Participants commented:

“Good opportunity to feel ‘wrong’ biopsy needle placement.”

“Highest yield part of the day was being able to... perform ‘bad’ aspirates or biopsies.”

When asked what made them most nervous about the sternal bone marrow procedure, all six hematology fellows that received focused sternal aspirate teaching feared damaging surrounding structures by mis-landmarking. Following the workshop, five of the six participants stated

they would be comfortable performing the procedure on a patient.

Table 1. Characteristics of bone marrow biopsies performed by trainees and staff hematologists

	Mean biopsy length, mm (SD)	% of biopsy that is marrow, % (SD)	Biopsies that yielded a diagnosis, n (%)
Trainees (n = 4)	13.35 (5.5)	85.55 (15.1)	41/46 (93.5)
Staff hematologists (n = 3)	15.88 (5.5)	80.15 (16)	39/42 (92.9)

Next steps

The workshop requires procedural equipment, cadavers, and an anatomist which may limit how easily it can be adopted by other centres. However, this workshop may offer an opportunity for direct observation of trainee skills, and demonstrates the feasibility of collecting trainee bone marrow specimen length and diagnostic yield as a measure of procedural competence.

Conflicts of Interest: The authors have no relevant conflicts of interest to disclose.

Funding: This work was supported by the Canadian Institute for Health Research under a Health Professional Student Research Award.

References

1. Cottam WW. Adequacy of medical school gross anatomy education as perceived by certain postgraduate residency programs and anatomy course directors. *Clin Anat*. 1999;12(1):55-65. [https://doi.org/10.1002/\(SICI\)1098-2353\(1999\)12:1<55::AID-CA8>3.0.CO;2-O](https://doi.org/10.1002/(SICI)1098-2353(1999)12:1<55::AID-CA8>3.0.CO;2-O)
2. McLaughlin S, Fitch MT, Goyal DG, et al. Simulation in graduate medical education 2008: A review for emergency medicine. *Acad Emerg Med*. Vol 15. John Wiley & Sons, Ltd; 2008:1117-1129. <https://doi.org/10.1111/j.1553-2712.2008.00188.x>
3. Kovacs G, Levitan R, Sandeski R. Clinical cadavers as a simulation resource for procedural learning. Promes SB, ed. *AEM Educ Train*. 2018;2(3):239-247. <https://doi.org/10.1002/aet2.10103>
4. Oxentenko AS, Ebbert JO, Ward LE, et al. A multidimensional workshop using human cadavers to teach bedside procedures. *Teach Learn Med* 2003;15(2):127-130. https://doi.org/10.1207/S15328015TLM1502_10

¹ Cost can be significantly reduced by using cadavers prior to a planned surgical skills workshop as the bone marrow biopsy does not cause significant damage to the cadavers. In addition, use of prosected specimens from an anatomy collection can reduce cost.

Appendix A

Pre-Workshop Survey

Level of training?

Where did you complete your General Internal Medicine training?

When were you first taught the bone marrow biopsy procedure?

Who first taught you the bone marrow biopsy procedure? (e.g. internist, hematologist)

Have you received formal bone marrow biopsy teaching during your Hematology training?

Did this teaching reference the relevant anatomy?

Approximately how many bone marrow biopsies have you completed to date?

What do you find the biggest challenge of bone marrow procedures?

How would you rate your comfort with landmarking the posterior superior iliac spine (PSIS) bone marrow procedure? (1 = not comfortable, 3 = somewhat comfortable, 5 = very comfortable)?

How would you rate your knowledge of anatomy relevant to bone marrow procedures? (1 = not knowledgeable, 3 = somewhat knowledgeable, 5 = very knowledgeable)?

How would you rate your confidence in the sample quality of your bone marrow biopsies? (1 = not confident, 3 = somewhat confident, 5 = very confident)?

Have you ever performed a sternal bone marrow aspirate on a patient? (Y/N)

If yes, on average, how many do you perform per year?

If yes, when was the last time that you performed a sternal bone marrow aspirate on a patient?

Have you ever received formal teaching on performing sternal bone marrow procedures?

If yes, did the teaching reference the relevant anatomy?

What do you find the most difficult aspect/challenge of carrying out this procedure? Or, if you have not done it before, what makes you most nervous?

Have you ever encountered any complications from performing a sternal bone marrow procedure? (Y/N)

If yes, please describe:

Post-Workshop Survey

Rate the effectiveness of teaching provided? (1 = least effective, 7 = most effective)

What aspect of today's session was most helpful?

What impact did today's session have on your comfort with bone marrow procedures? (1 = no change, 3 = some improvement, 5 = significant improvement)

What impact did today's session have on your knowledge of the relevant anatomy? (1 = no change, 3 = some improvement, 5 = significant improvement)

What impact do you expect today's session will have on your bone marrow biopsy technique? (1 = no change, 3 = some adjustments, 5 = significant change)

If you participated in sternal aspirate training:

Are you comfortable landmarking the sternal bone marrow aspirate? (Y/N)

Do you feel comfortable with your knowledge of the anatomy relevant to this procedure (nearby nerves, blood vessels, etc.)? (Y/N)

After today's session, would you feel comfortable performing a sternal aspirate on a patient? (Y/N)

Feedback/Comments?

eSupplement

Workshop layout:

Part 1a: A video reviewing relevant anatomy and bone marrow biopsy technique. Available via DVD/CD.¹

Part 1b: A review of prepared specimens led by an anatomy expert (see Figures A-G). We recommend discussing the following:

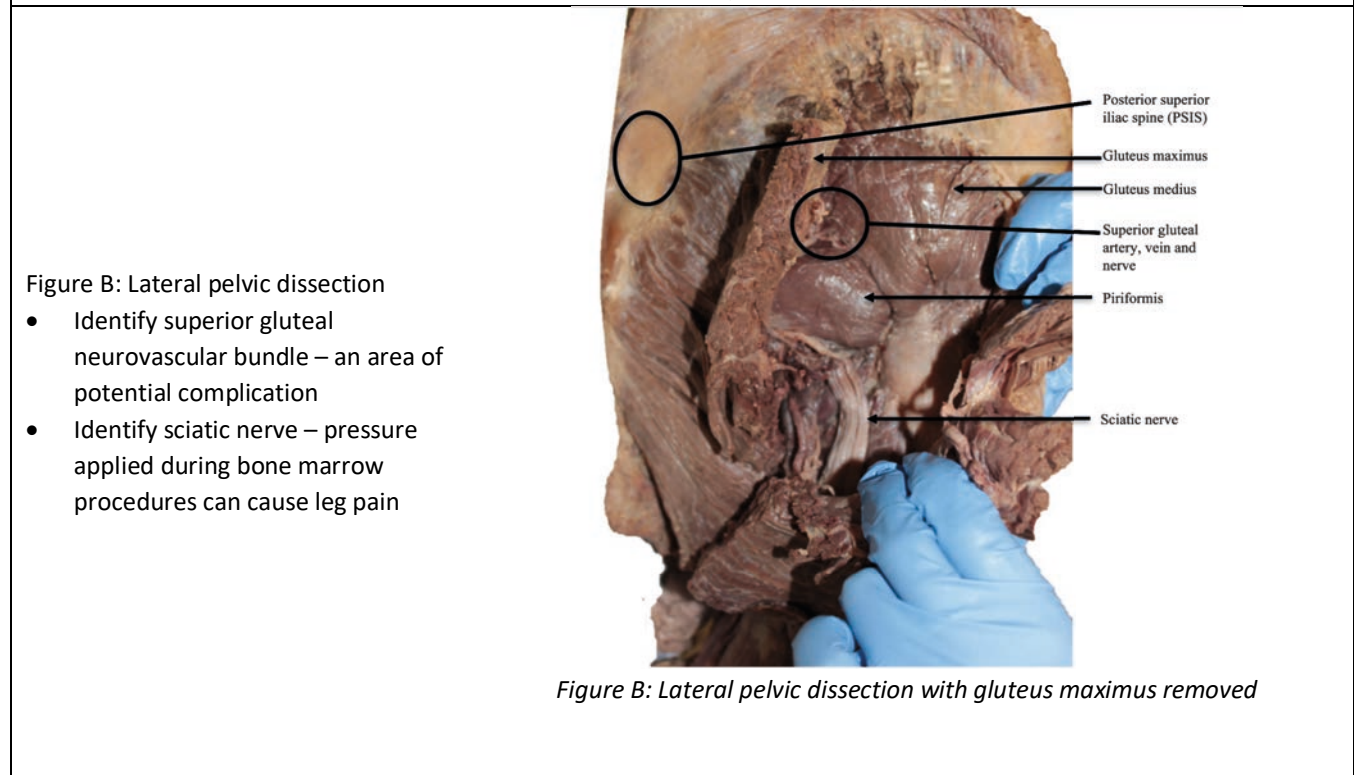
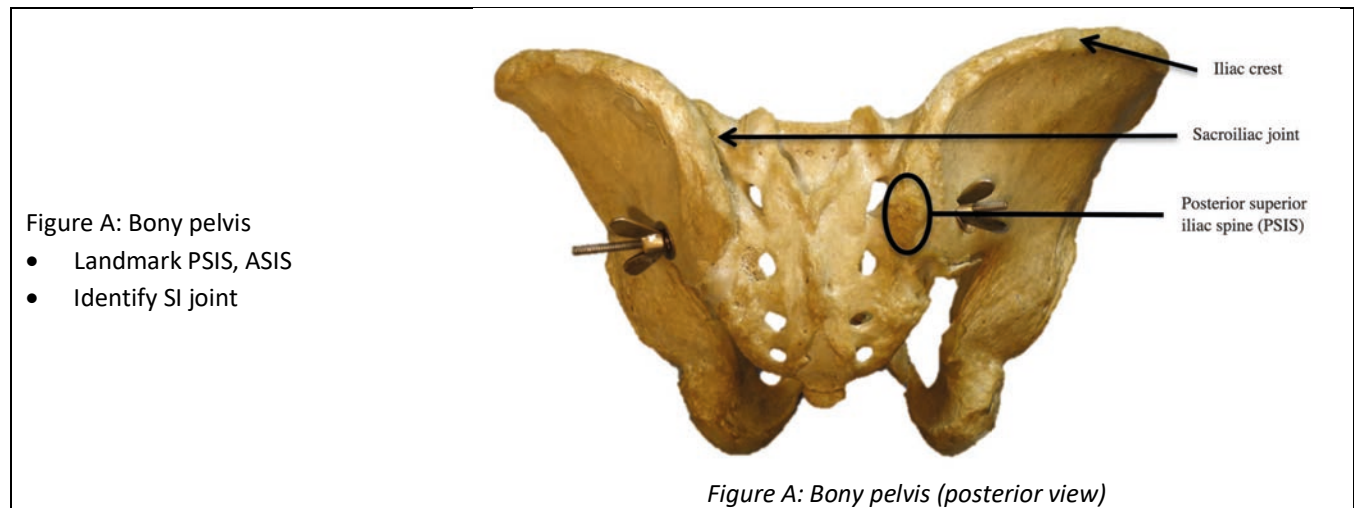


Figure C: Lateral pelvic dissection

- Identify superior gluteal neurovascular bundle
- Identify sciatic nerve

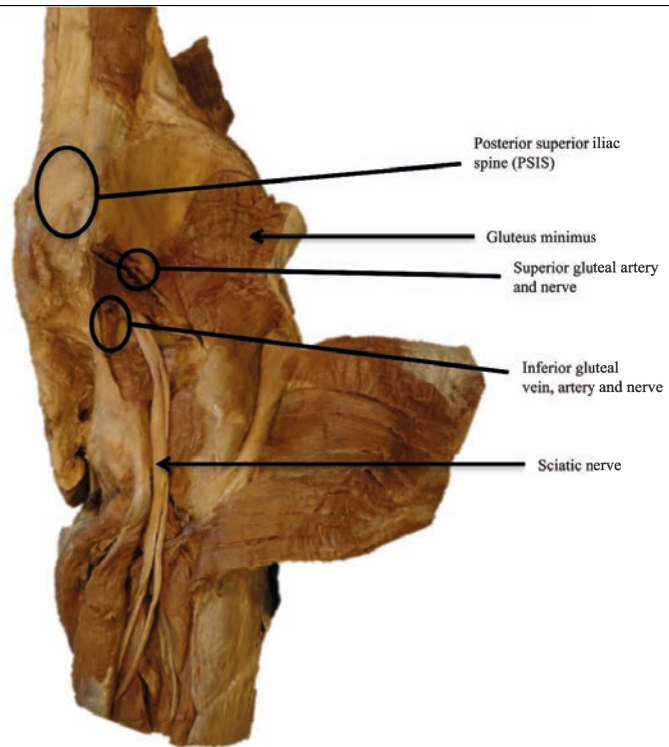


Figure C: Lateral pelvic dissection with *gluteus maximus* and *gluteus medius* removed

Figure D: Posterior pelvic dissection

- Identify superior gluteal neurovascular bundle
- Identify sciatic nerve

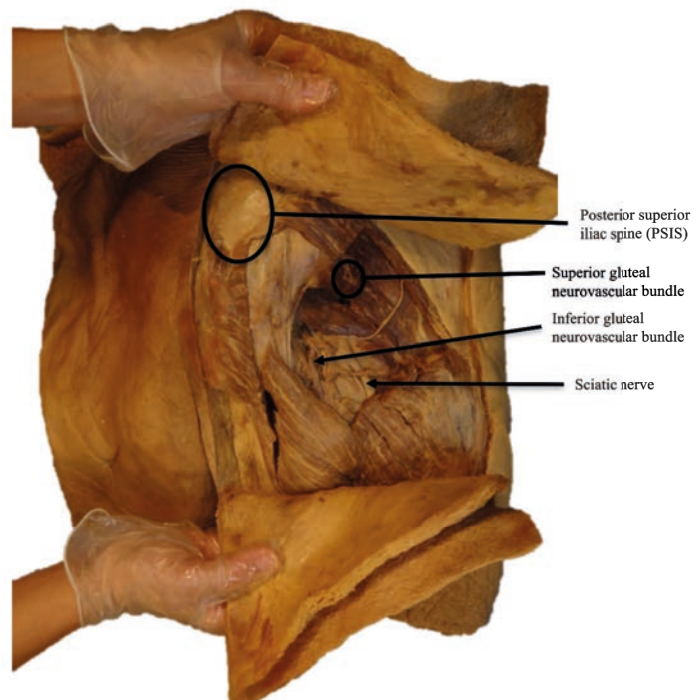


Figure D: Posterior pelvic dissection with *gluteus maximus* and *minimus* removed

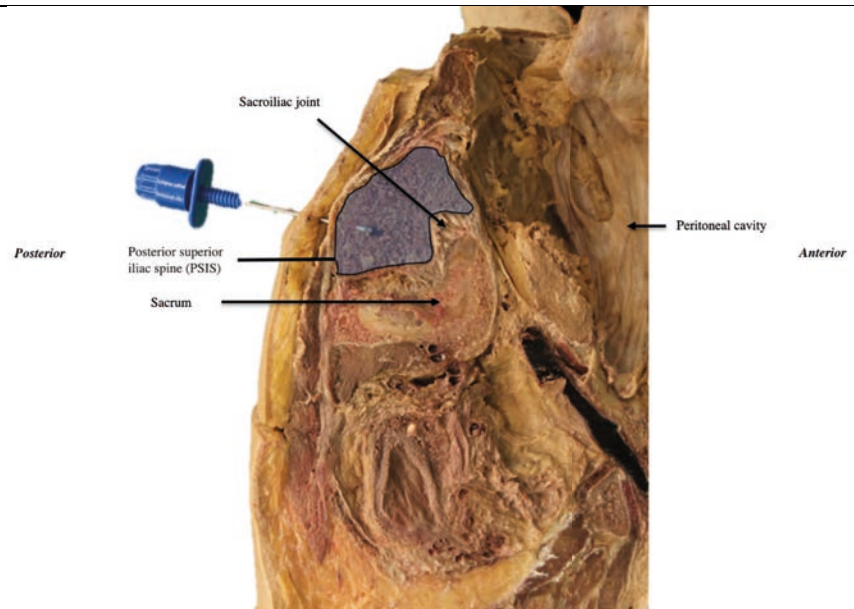


Figure E: Parasagittal pelvic section

- Note the depth of the bone at the PSIS

Figure E: Pelvis sectioned through the PSIS (parasagittal view with bone marrow biopsy needle in situ)

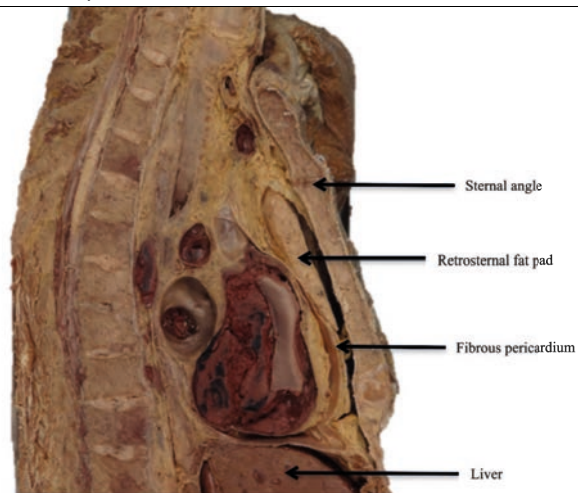


Figure F: Midsagittal thoracic section

- Landmark for sternal aspirate: 2nd or 3rd intercostal space
- Note the depth from sternum to pericardium

Figure F: Midsagittal thoracic section

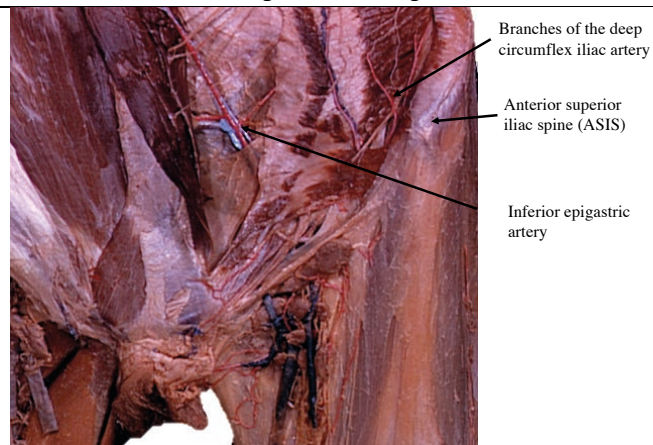


Figure G: Anterior pelvic dissection with abdominal wall resected

- Locate the ASIS
- Identify deep circumflex iliac artery/vein and inferior epigastric artery/vein – areas of potential complication

Figure G: Anterior pelvic dissection with abdominal wall resected²

Part 2: Hands-on practice of bone marrow procedures on cadavers.

We recommend cadavers of varying habitus to simulate clinical practice. A staff hematologist should begin by demonstrating the proper technique for PSIS and ASIS bone marrow biopsies and sternal bone marrow aspirates on a cadaver. A discussion of the advantages and disadvantages of each site is recommended (Table 2, available upon request).

Participants should practice:

- Bone marrow biopsies of the PSIS in the prone position and the ASIS in the supine position
- Bone marrow aspirate needle insertion into the sternum with sternal guard in place

Trainees are encouraged to practice each procedure 3-5 times and on at least two different cadavers. A staff hematologist should circulate to give participants feedback on their PSIS, ASIS and sternal sampling techniques.

Safety: We advise ensuring safety measures are taken in accordance with anatomy lab protocols to protect participants. These include appropriate participant footwear, good hand hygiene and donning protective gowns and gloves while handling specimens. All sharps (including scalpels, biopsy needles and aspirate needles) should be dealt with using caution and disposed of safely in accordance with the anatomy lab's policy.

References

1. Zeller M, Goldszmidt M, Cristancho S, Johnson M, Creces D, Mangel J. Bare bones: A return to anatomy for teaching bone marrow biopsy and aspirate procedures. MedEdPORTAL Publications. 2015. https://doi.org/10.15766/mep_2374-8265.10091
2. Bourn D. Figure 137-6: Dissection of female inguinal region. Bassett Collection of Stereoscopic Images of Human Anatomy Stanford Medicine Lane Medical Library.